

ASPECTE CLINICE ÎN CARDIOMIOPATIA DILATATIVĂ (CMD) LA SUGAR ȘI NOU-NĂSCUT

Mădălina Gilice¹, Sonia Tănăsescu², Mirela Soare², Alice Raica², Liviu Pop²

¹UMF „Carol Davila“, București

²Clinica II Pediatrie – UMF „Victor Babeș“, Timișoara

REZUMAT

Cardiomiopia (CMP) dilatativă se caracterizează prin dilatarea cavităților și prin diminuarea contractilității VS și/sau a VD. Se disting CMP idiopatice, familiale/genetice, virale și/sau imunologice, alcoolice/toxice sau CMP dilatative asociate cu boli cardiace cunoscute, dar la care gradul disfuncției miocardice nu este explicat de anomaliile hemodinamice sau de severitatea ischemiei. Clinica este dominată de insuficiență cardiacă, aritmii, tromboembolismul pulmonar, moarte subită.

În clinica noastră, în perioada nov. 2006 – ian. 2007 s-au diagnosticat 3 cazuri de CMD la nou-născut și la sugar. Diagnosticul pozitiv s-a realizat în prezența insuficienței cardiace în 2 cazuri, șoc cardiogen 1 caz.

În toate cazurile de insuficiență cardiacă cu debut precoce în perioada de nou-născut și sugar, ecocardiografia are rol decisiv în stabilirea diagnosticului de CMD, ceea ce permite uneori ca aplicarea unei scheme terapeutice complexe să amelioreze evoluția bolii și prognosticul pe termen lung.

Cuvinte cheie: cardiomiopatie dilatativă, insuficiență cardiacă, sugar, nou-născut

INTRODUCERE

Cardiomiopia (CMP) dilatativă se caracterizează prin dilatarea cavităților și diminuarea contractilității VS și/sau VD. Se disting CMP idiopatice, familiale/genetice, virale și/sau imunologice, alcoolice/toxice sau CMP dilatative asociate cu boli cardiace cunoscute, dar la care gradul disfuncției miocardice nu este explicat de anomaliile hemodinamice sau de severitatea ischemiei (1,2,3,4). Anatomopatologic sunt prezente leziuni nespecifice. Clinica este dominată de insuficiența cardiacă, aritmii, tromboembolism pulmonar, moarte subită (5,6).

În Clinica II Pediatrie în perioada noiembrie 2006 – ianuarie 2007 s-au diagnosticat 3 cazuri de cardiomiopatie dilatativă la nou-născut și sugar. Diagnosticul pozitiv s-a realizat în prezența insuficienței cardiace în 2 cazuri, șoc cardiogen 1 caz.

Observație clinică nr. 1

O.I., sex feminin, în vârstă de 7 luni, se internează în Clinica II Pediatrie (FO 3722/2006) pentru tuse,

rinore sero-mucoasă, vărsături. Este copil de rang III, născut la 9 luni cu greutatea la naștere 3.100 g, T = 48 cm, IA = 9, adaptare neonatală corespunzătoare. Alimentat natural 3 luni, diversificat la 4 luni, alimentat incorect cu exces de lapte și făinos. Antecedente personale patologice: repetate infecții de tract respirator superior.

Afirmativ, simptomatologia actuală debutează cu 2 zile anterior internării cu rinoree sero-mucoasă, tuse, vărsături. Nu a beneficiat de nici un tratament. De asemenea, menționăm prezența dispneei la alimentație de aproximativ 2 luni.

Examen obiectiv la internare: G 5.000 g, PC 38 cm, PT 37 cm, PA 38 cm, T 60 cm cu stare generală relativ bună, subfebril 37,8 C, tegumente palide, țesut celular subcutanat slab reprezentat pe torace, membre. FA 2/2 cm, normotensivă, torace ușor evazat la baze, mătăni condrocostale prezente. Prezintă dispnee de efort, rinoree, ampliații respiratorii simetrice bilateral, murmur vezicular prezent, rare raluri ronflante. Arie precordială de aspect normal, șoc apexian spațiul IV intercostal pe linia mediană, zgomote cardiace ritmice, tahicardice cu AV 160b/min, suflu sistolic gr. II/6 parasternal stâng.

Adresa de corespondență:

Dr. Sonia Tănăsescu, Universitatea de Medicină și Farmacie „Victor Babeș“, Piața Eftimie Murgu, nr. 2, cod 300041, Timișoara
e-mail: sonia.tanasescu@yahoo.com

Faringe congestionat, abdomen moale, ficat cu marginea inferioară la 3,5-4 cm sub rebordul costal, splina nepalpabilă, scaune de aspect normal. Micțiuni spontane. ROT și cutanate prezente, fără semne de iritație de meningeană. Organe de simț relații normale.

Diagnosticul la internare: rinofaringobronșită acută. Suspect malformație congenitală de cord necianogenă. Insuficiență cardiacă acută. Sindrom anemic. Rahitism carențial. Distrofie gr II.

Investigații paraclinice Hb 9,6 g%, H 3.400.000/mmc, L 5.700/mmc, Tr 200.000/mmc, N 0, S 40%, E 2%, B 0, L 54%, M 4%, VSH 2/5 mm. Examen de urină: albumină absentă, sediment cu 1-2 leucocite/câmp, rare epitelii plate; aspirat hipofaringian flora nepatogenă, proteinemie 6,8 g%.

Radiografie cardiotoracică: desen peribronhovascular ușor accentuat. Cord cu bombarea arcului aortic stâng.

EKG: tahicardie sinusală, 146/min, ax QRS intermediar, unde Q DIII, Avf, hipertrofie ventriculară stângă, T negativ DIII, V1-V3 – tulburări de repolarizare (Fig. 1).

Ecocardiografie: Ao 0,9 cm, AS 1,2 cm, VS 2,3/3,1 cm, FE 0,64, FS 32%, distanța E-sept 1,5 cm, mișcări sincrone ale septului față de peretele posterior, fără lichid în pericard. Dg cardiomiopatie (Fig. 2).

Observație clinică nr. 2

Sugar U.R. în vârstă de 6 luni, se internează în Clinica II Pediatrie (FO 198/2007) pentru tuse,

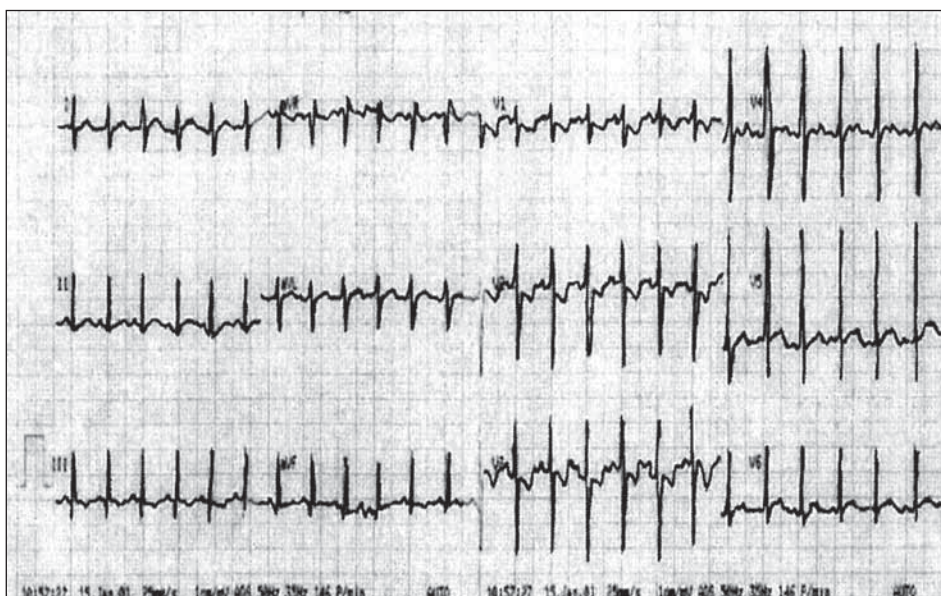


FIGURA 1

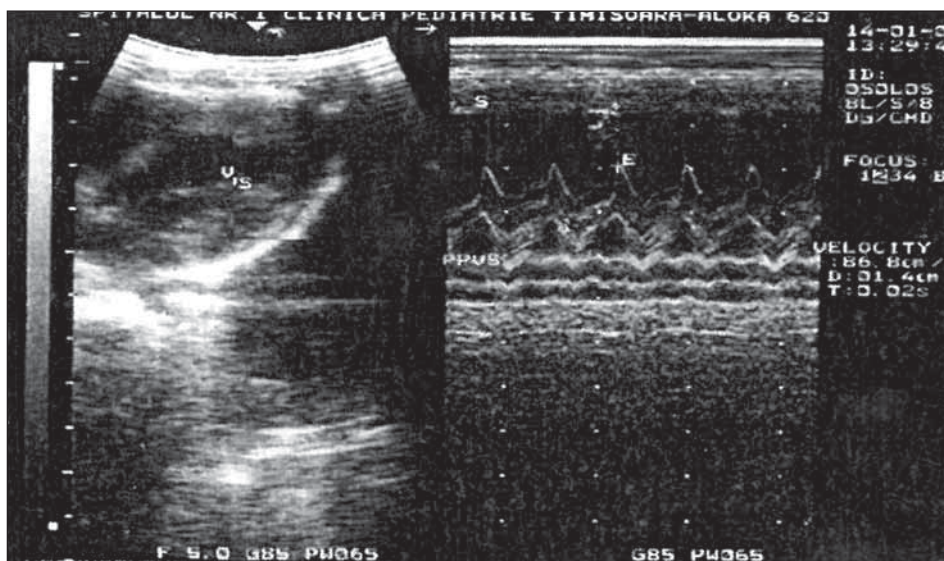


FIGURA 2

asociată inițial cu dispnee de efort, apoi cu dispnee expiratorie, wheezing. A beneficiat de tratament antibiotic în asociere, diagnosticul fiind de pneumonie trenantă. Absența răspunsului favorabil la tratamentul aplicat a impus internarea în Clinica II Pediatrie.

La internare se prezintă cu G = 7.400 g, PC 43 cm, PT 42 cm, PA 46 cm, T 75 cm cu stare generală influențată, afebril, tegumente curate, mai palide, țesut celular subcutanat normal reprezentat, FA 2/2 cm normotensivă. Prezintă tuse spastică, dispnee expiratorie wheezing, FR 66 r/min, stetacustic pulmonar murmur vezicular prezent, raluri subcrepitante pe ambele arii pulmonare. Zgomote cardiace ritmice, tahicardice AV 180 b/min, suflu sistolic gr

II/6 pluriorganic. Abdomen moale, ficat la 4,5 cm sub rebordul costal drept, splină acrosabilă. Tranzit intestinal prezent, scaun normal, micțiuni prezente.

Diagnostic de internare: pneumopatie acută lobulară. Insuficiență cardiacă acută. Suspect malformație congenitală de cord.

Investigații paraclinice: Hb 10,5 g%, H 3.700.000/mmc, L 5800/mmc, Tr 200.000/mmc, N 0, S 39%, E 1%, B 0, L 55%, M 5%. Examen de urină: albumină absent, sediment cu 1-2 leucocite/câmp, rare epitelii plate; aspirat hipofaringian floră nepatogenă, proteinemie 6,5 g%.

Radiografie cardio-pulmonară: desen interstițial accentuat bilateral, cardiomegalie globală.

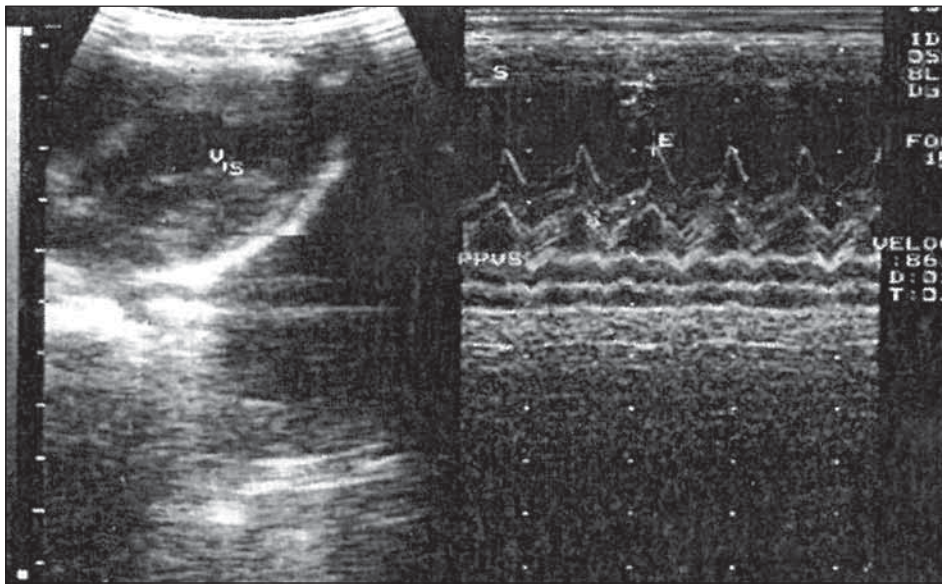


FIGURA 3. Aspectul ecocardiografic: Ao 0,9 cm, AS 1,2 cm VS 2,3/3,1 cm, FE 0,64, FS 32%, distanța E-sept 1,5 cm, mișcări sincrone ale septului față de peretele posterior, fără lichid în pericard. Dg. cardiomiopatie dilatativă

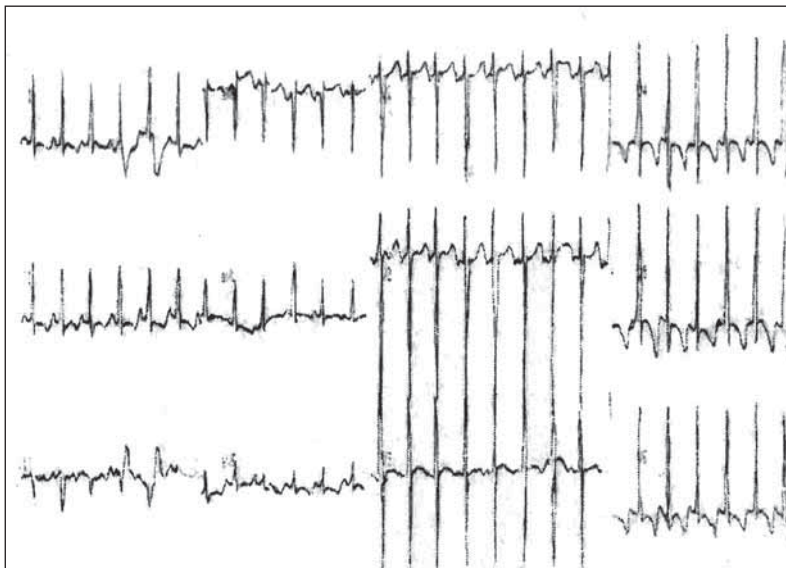


FIGURA 4. Aspectul EKG: tahicardie sinusală, AV 169 b/min, ax QRS la stânga, P pulmonar în DII, HVS indice SokolovLion 52 mm, tulburări de repolarizare, ST alungit

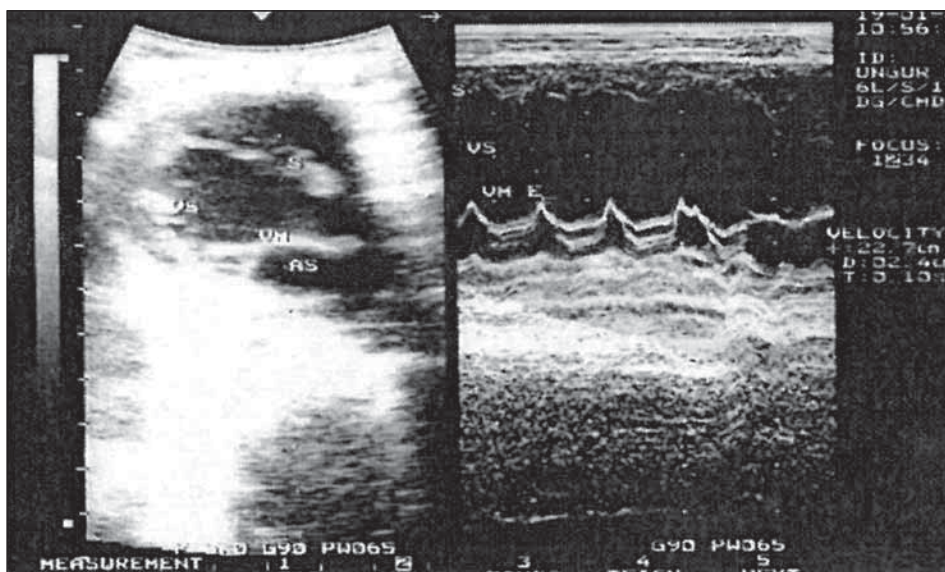


FIGURA 5. Aspectul ecocardiografic: Ao 1,1, As 1,6 cm, VS 3,4/3,8 cm, VM aproape de peretele posterior al VS, mișcări limitate ale peretelui posterior al VS față de sept. FE 0,24, FS 11%. Distanța E-sept 2,4 cm. Dg: cardiomiopatie dilatativă

A beneficiat de tratament cu Digoxin 0,02 mg/kg/zi, administrat oral, asociat cu Furosemid 5 mg/zi inițial zilnic, apoi de două ori pe săptămână.

Evoluție favorabilă cu reducerea dimensiunilor ficatului, dispariția dispneei de efort, creștere ponderală.

A beneficiat de tratament cu lanatozid C 0,04 mg/kg/zi doză de atac, apoi 0,02 mg/kg/zi doză de întreținere, furosemid. Se menține tahicardic, cu zgomote cardiace ritmice, suflu sistolic gr II/6 la vârf. Se modifică terapia cu administrarea de Dobutamină 5 ug/kg/min. în perfuzie continuă 48 de ore, cu scăderea dozei la 2,4 ug/kg/min. încă 24 de ore, apoi administrare de digoxin oral 0,02 mg/kg/zi. Evoluție favorabilă cu ameliorarea FE și FS și a manifestărilor clinice (tahicardie, dispariția suflului sistolic, reducerea hepatomegaliei). Se continuă terapia la domiciliu cu Digoxin 0,125 mg/zi po, Furosemid 7 mg/zi po, discontinuu.

Observație clinică nr. 3

Diagnostic la internare: infecție materno-fetală. Insuficiență cardiacă acută.

Investigațiile paraclinice relevă:

Radiografie cardiopulmonară: desen vasculo-interstițial ușor accentuat la nivelul hililor. Cardiomegalie globală.

Ecocardiografie: Ao 0,8 cm, AS 1,1 cm, VS 1,4/1,8 cm, orificiul Botallo permeabil, VD mult mărit. Cavități ventriculare mari. Dg. cardiomiopatie dilatativă.

Se instituie tratament cu antibiotice în asocieră, Netromicină 25 mg/zi iv, Furosemid 3mg/zi iv, Dopamină 7ug/kg/min, oxigen.

Evoluție sub tratament nefavorabilă, cu șoc cardiogen la 3 ore de la internare și deces.

Protocol de autopsie nr. 4102/2006 – hemoragie subarahnoidiană. Ventriculi laterali mult dilatați. Hemoragie punctiformă în masa cerebrală. Cardiomegalie globală: cord 5,5/5,5/3 cm cu cavități ventriculare mult dilatate mai ales ventriculul drept. Peretele ventriculului drept mult îngroșat – 3 mm grosime. Orificiul Botallo deschis. Plămâni aerați, proba docemaziei pozitivă. Hepatomegalie cu ficat 12/7/4 cm de consistență fermă. Splenomegalie cu stază splenică. Rinichi și suprarenale de aspect normal, adenopatie mezenterică, ascită de cca 20-30 ml lichid serocitrin.

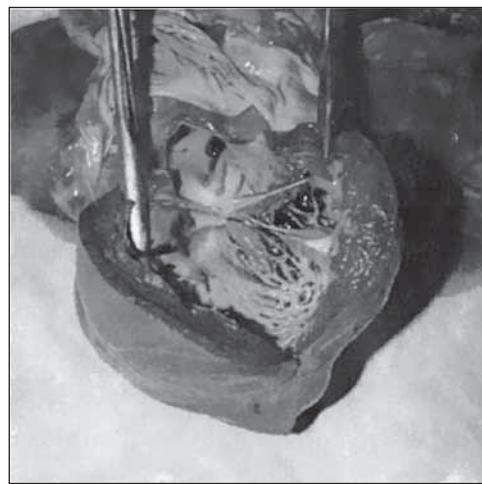

FIGURA 6. Aspectul cordului cu cord 5,5/5,5/3 cm, cu cavități ventriculare mult dilatate, mai ales ventriculul drept. Peretele VD mult îngroșat – 3 mm grosime, orificiul Botallo permeabil

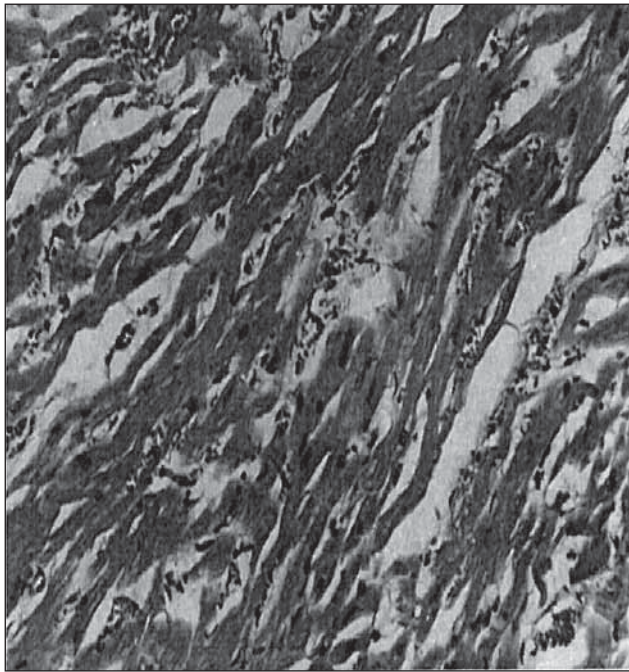


FIGURA 7. Aspectul microscopic: leziuni nespecifice cu fibre miocardice aliniate normal, cu nucleii hipertrofici, infiltrat inflamator limfocitar interstițial

CONCLUZII

1. Insuficiență cardiacă cu cardiomiopatie dilatativă care a evoluat spre șoc cardiogen cu deces, este mai frecventă la nou-născut.
2. Tulburări de ritm cu insuficiență cardiacă, cardiomiopatie dilatativă cu hemodinamică bună, posibilitate evolutivă la sugar. Pneumopatie trenantă cu insuficiență cardiacă, cardiomiopatie dilatativă cu prăbușirea hemodinamicii cardiace, posibilitate evolutivă la sugar, de evitat printr-un diagnostic diferențial larg care să includă și cardiomiopatia dilatativă.
3. Aportul benefic al ecocardiografiei în diagnosticul diferențial al insuficienței cardiace la nou-născut și sugar.

Clinical aspects in dilated cardiomyopathy in newborns and infants

Mădălina Gilice¹, Sonia Tănăsescu², Mirela Soare², Alice Raica², Liviu Pop²

¹University of Medicine and Pharmacy "Carol Davila", Bucharest

²Pediatrics Clinic no. 2, University of Medicine and Pharmacy, Timisoara

ABSTRACT

Dilated cardiomyopathy (DCM) is characterized by the dilation of cavities and a reduction in the LV and/or RV force of contraction. There are idiopathic, family/genetic, viral and/or immunologic as well as alcoholic/tox cardiomyopathies, or dilated DCMs associated with known cardiac conditions where the degree of the myocardial dysfunction is not explained by the hemodynamic anomalies or by the severity of the ischemia. The cases admitted in the clinic present mostly symptoms such as: heart failure, arrhythmia, pulmonary thromboembolism and sudden death.

During November 2006 and January 2007, the medical personnel in the 2nd Pediatric Clinic diagnosed 3 cases of dilated cardiomyopathy in newborns and infants. The positive diagnosis was made in the presence of heart failure (2 cases) and cardiogenic shock (1 case).

In all cases of congestive heart failure with early onset in the newborn or infant period, the cardiac ultrasound has a decisive role in establishing the diagnosis of CMD. This allows applying a complex therapeutical plan and sometimes improve the progress of this affection and long term prognosis.

Key words: dilated cardiomyopathy, heart failure, newborns and infants

INTRODUCTION

Dilated cardiomyopathy (DCM) is characterized by the dilation of cavities and a reduction in the LV and/or RV force of contraction. There are idiopathic, family/genetic, viral and/or immunologic as well as alcoholic/tox cardiomyopathies, or dilated DCMs associated with known cardiac conditions where the degree of the myocardial dysfunction is

not explained by the hemodynamic anomalies or by the severity of the ischemia (1,2,3,4). The anatomopathological signs are represented by non-specific lesions. The cases admitted in the clinic present mostly symptoms such as: heart failure, arrhythmia, pulmonary thromboembolism and sudden death (5,6).

During November 2006 and January 2007, the medical personnel in the 2nd Pediatric Clinic dia-

gnosed 3 cases of dilated cardiomyopathy in newborns and infants. The positive diagnosis was made in the presence of heart failure (2 cases) and cardiogenic shock (1 case).

Clinical observation no. 1

O.I., female, aged 7 months, was admitted to the 2nd Pediatric Clinic (Observation Sheet 3722/2006) with cough, seromucous rhinorrhea and vomiting. It was a rank 3 child, born at 9 months, with the weight at birth of 3,100 g, T=48 cm, IA=9 (Apgar score) and adequate neonatal adaptation. The child was breastfed for 3 months, then food diversification was started at 4 months and incorrectly fed with an excess of milk and floury products.

Pathological personal antecedents: repeated infections in the upper respiratory tract.

The symptoms started 2 days before the child was admitted, including cough, seromucous rhinorrhea and vomiting. No treatment was administered. Also, the dyspnea caused the poor feeding of the child for approximately 2 months.

The objective examination before the patient was admitted to hospital: body weight: 5000g, cranial perimeter: 38cm, thoracic perimeter: 37cm, abdominal perimeter: 38 cm, height: 60 cm, in relatively good health, subfebrile temperature of 37.8°C, pale teguments, minimal subcutaneous tissue on the trunk and limbs. Anterior fontanelle 2/2 cm normotensive, slightly enlarged thorax, flaring of the costo-chondral rib ends. The patient displays effort dyspnoea, rhinorrhea, bilaterally symmetric respiratory activity, vesicular murmur present, infrequent sonorous wheeze. Normal aspect of pre-

cordium, apexian shock sp IV, rhythmic heart sounds, tachycardia with 160 beats/minute, grade 2/6 systolic murmur in the left parasternal area. Congested pharynx, soft abdomen, liver 3.5 – 4 cm under the right lower rib, impalpable spleen, normal stools. Spontaneous urination. Present osteotendinous and cutaneous reflex responses, without signs of meningeal irritation. Normal functioning of the sense organs.

Diagnostic upon admission to hospital: acute rhino-pharyngo-bronchitis. Suspect of non-cyanogenic congenital heart defect. Acute heart failure. Anemic syndrome. Nutritional rickets. 2nd degree dystrophia.

Paraclinical investigations: Hb: 9.6 g%, H: 3,400,000/mmc, L: 700/mmc, Tr: 200,000/mmc, N: 0, S: 40%, E: 2%, B: 0, L: 54%, M: 4%, VSH 2/5 mm. Urine exam: albumin absent, sediment 1-2 leukocytes/field, rare flat epithelial cells; non-pathogenic flora in the hypopharyngeal aspirate, proteinuria: 6.8%

Cardiothoracic radiography: slightly thickened peribronchovascular lines. Heart with enlarged left aortic arch.

EKG: sinus tachycardia, 146/min, intermediary QRS axis, Q waves in lead III and in lead aVf, left ventricular hypertrophy, inverted T-waves in the right precordial leads (V1-3) and in lead III – repolarization abnormalities (Fig. 1).

Echocardiography: Aorta: 0.9 cm, Left atrium: 1.2 cm, Left ventricle: 2.3/3.1 cm, FE: 0.64, FS: 32%, mitral E-septum distance: 1.5 cm, synchronous septal-to-posterior wall motion, no liquid in the pericardium. Diagnostic: cardiomyopathy (Fig. 2).

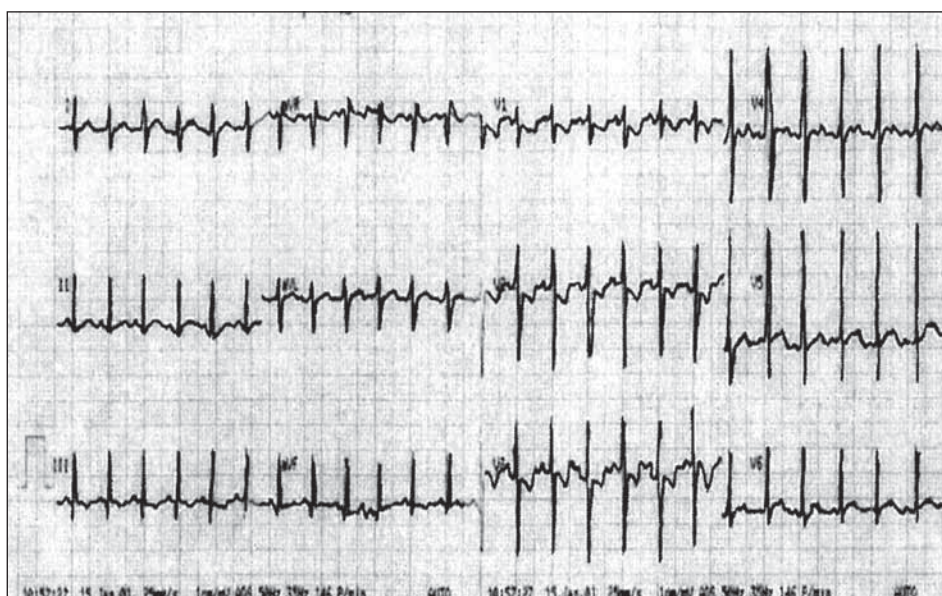


FIGURE 1

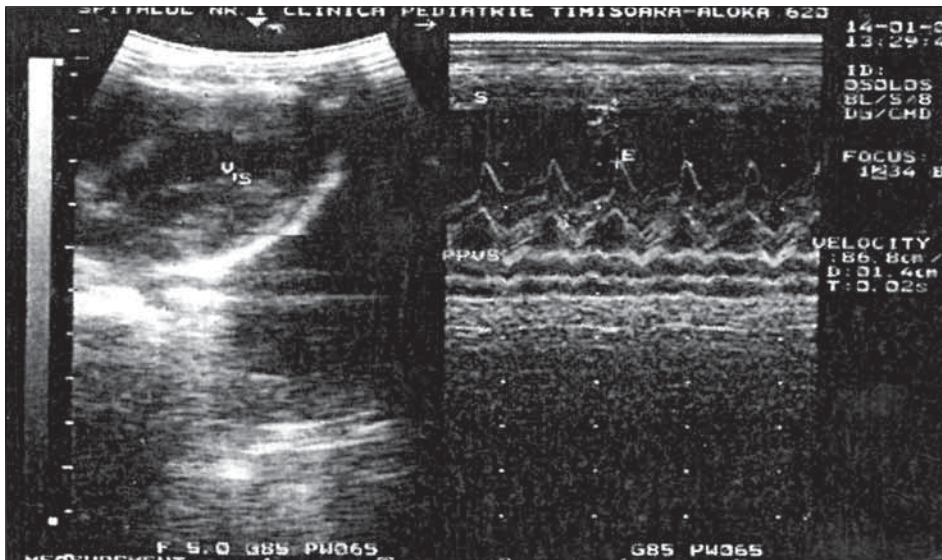


FIGURE 2

Clinical observation no. 2

Infant U.R., aged 6 months, was admitted to the 2nd Pediatric Clinic (Observation Sheet 198/2007) with cough, initially associated with dyspnea on effort and then with expiratory wheezing dyspnea. The patient was treated with antibiotics, being diagnosed with chronic pneumonia. The lack of positive response to the administered treatment required the patient to be admitted in the 2nd Pediatric Clinic.

Upon admission to hospital, the patient is examined and found as follows: body weight: 7,400 g, cranial perimeter: 43 cm, thoracic perimeter: 42 cm, abdominal perimeter: 46 cm, height: 75 cm, with general altered health status, afebrile, anterior fontanelle 2/2 cm normotensive.

The patient has spasmodic cough, expiratory wheezing dyspnea, respiratory rate is 66 breaths per minute, vesicular murmur present upon examination with the acoustic stethoscope, subcrepitant rales in both pulmonary areas. Rhythmic heart sounds, tachycardia with 180 beats/minute, grade 2/6 pluriorifical systolic murmur. Soft abdomen, liver 4.5 cm under the right lower rib, palpable spleen. Bowel movement, normal stool, normal urination.

Diagnostic upon admission to hospital: acute lobar pneumonia. Acute heart failure. Suspect of congenital heart defect.

Paraclinical investigations: Hb: 10,5 g%, H: 3,700,000/mmc, L: 5800/mmc, Tr: 200,000/mmc, N: 0, S: 39%, E: 1%, B: 0, L: 55%, M: 5%. Urine exam: albumin absent, sediment 1-2 leukocytes/

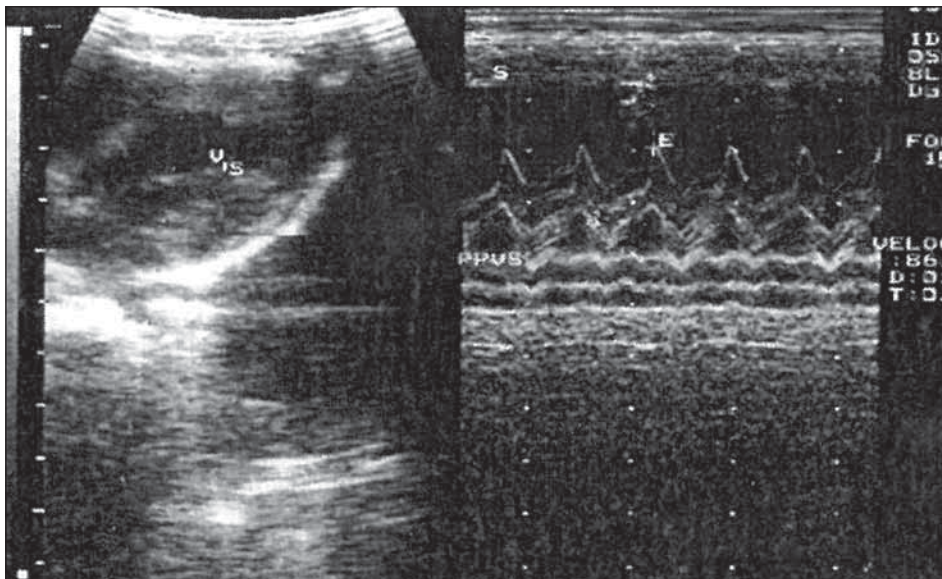


FIGURE 3. Echocardiography: aorta: 0.9 cm, Left atrium: 1.2 cm, Left ventricle: 2.3/3.1 cm, FE 0.64, FS 32%, mitral E-septum distance: 1.5 cm, synchronous septal-to-posterior wall motion, no liquid in the pericardium. Diagnostic: dilated cardiomyopathy

field, rare flat epithelial cells; non-pathogenic flora in the hypopharyngeal aspirate, proteinuria: 6.5%.

Cardio-pulmonary radiography: increased bilateral thickening of the lung interstitium, global cardiomegaly.

The patient received treatment with Digoxin 0.02mg/kg bw/day, oral, associated with Furosemid 5mg/day, initially every day, then twice/week.

Favourable evolution was noted, resulting in the reduction in liver size, disappearance of the dyspnea on effort and weight gain.

The patient was treated with Lanatoside C in a loading dose of 0.04 mg/bw kg/day, then Furosemide 0.02 mg/bw kg/day as maintenance dose. The patient keeps showing tachycardia, with rhythmic heart sounds and grade 2/6 systolic murmur at apex. The treatment was modified. The patient is administered Dobutamine 5 µg/bw kg/min in continuous infusion for 48 hours, then the dose is lowered to 2.4 µg/bw kg/min for another 24 hours, then orally administered Digoxin 0.02 mg/bw kg/day. Favourable evolution with improvement in FE and FS and

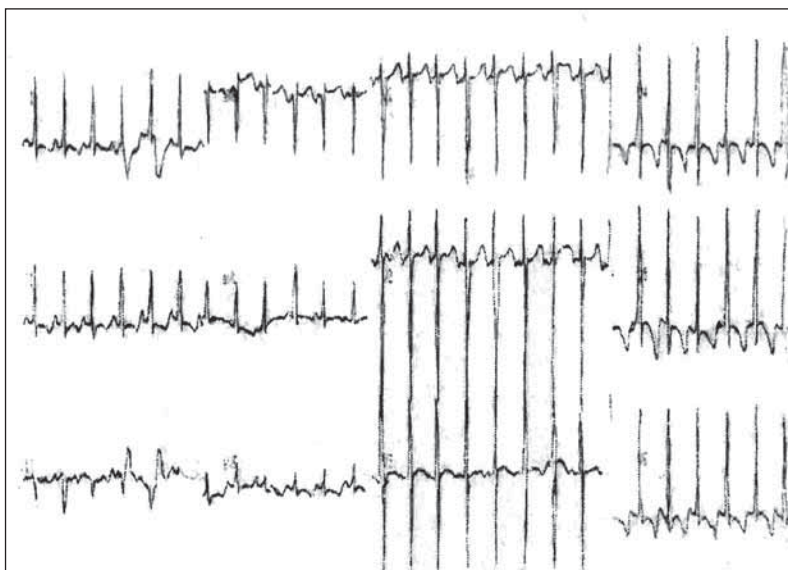


FIGURE 4. EKG examination: sinus tachycardia with AV block, 169 beats/min, left QRS axis deviation, pulmonary peaked P waves in lead II, left ventricular hypertrophy diagnosed electrocardiographically by the Sokolow-Lyon index: 52 cm, repolarization abnormalities, ST segment elevation

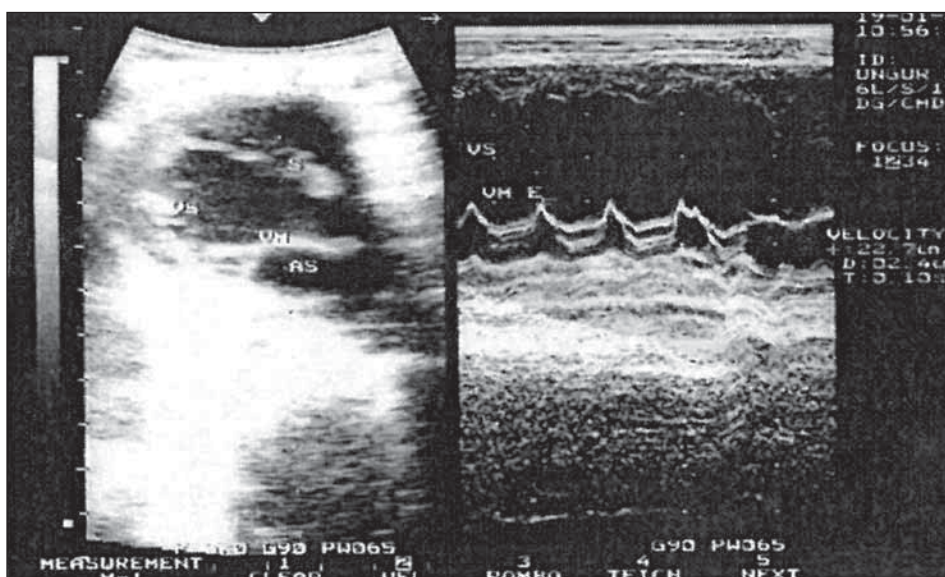


FIGURE 5. Echocardiographic aspect: Aorta: 1.1 cm, Left atrium: 1.6 cm, Left ventricle: 3.4/3.8 cm, mitral valve close to the posterior wall of the left ventricle with "fish-mouth"-shaped orifice, limited septal-to-posterior wall motion, FE: 0.24, FS: 11%, mitral E-septum distance: 2.4 cm. Diagnostic: dilated cardiomyopathy

clinical symptoms (tachycardia, disappearance of systolic murmur, reduction of hepatomegaly). The treatment is continued at home with Digoxin 0.125 mg/day and Furosemide 7 mg/day, both administered orally, and with discontinuous administration.

Clinical observation no. 3

Diagnostic upon admission to hospital: mother to baby infection. Acute heart failure.

Paraclinical investigations indicate:

Cardio-pulmonary radiography: appearances of interstitial and alveolar opacity with slightly thickened lines at the level of the hilum. Global cardiomegaly.

Echocardiography: Aorta: 0.8 cm, Left atrium: 1.1 cm, Left ventricle: 1.4/1.8 cm, pervious duct of Botallo, Right ventricle excessively enlarged. Large ventricular cavities.

Diagnostic: dilated cardiomyopathy.

The patient is given a treatment with associated antibiotics: Netromycin 25 mg/day by intravenous infusion, Furosemide 3 mg/day by intravenous infusion, Dopamine 7 µg/bw kg/min and oxygen.

Unfavourable evolution under treatment with cardiogenic shock 3 hours after admission to hospital and death.

Autopsy protocol no. 4102/2006 – subarachnoid hemorrhage. Very dilated lateral ventricles. Punctate hemorrhage within the brain parenchyma. Global cardiomegaly: heart size: 5.5/5.5/3 cm, with very enlarged ventricular cavities, especially the

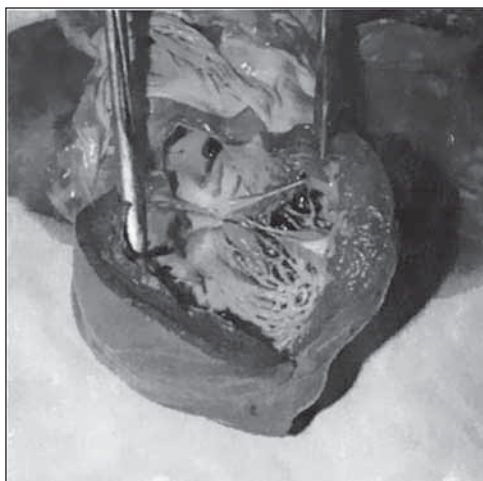

FIGURE 6. Heart aspect – size: 5.5/5.5/3 cm, with very enlarged ventricular cavities, especially the right ventricle. Large thickening of the anterior right ventricular wall – 3 mm thick. Pervious duct of Botallo

right ventricle. Large thickening of the anterior right ventricular wall – 3 mm thick. Pervious duct of Botallo. Aerated lungs – positive hydrostatic docimasia. Hepatomegaly – liver 12/7/4 cm in size, firm consistency. Splenomegaly with spleen stasis. Normal aspect of the kidneys and adrenal glands, mesenteric adenitis, ascites of approx. 20-30 ml serous citrine fluid.

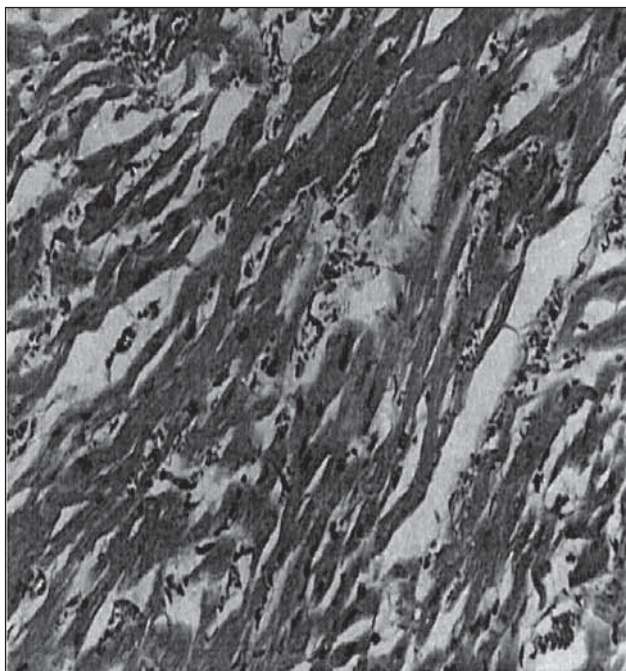


FIGURE 7. Microscopic examination: non-specific lesions with normally aligned myocardial fibres, with hypertrophic nuclei, interstitial leukocyte inflammatory infiltration

CONCLUSION

1. Heart failure with dilated cardiomyopathy, evolving towards cardiogenic shock and death, most frequently encountered in the newborn.
2. Arrhythmias with heart failure, dilated cardiomyopathy with good heart rate, possibility of evolution in infants. Chronic pneumonia with heart failure, dilated cardiomyopathy with a sharp drop in heart rate, possibility of evolution in infants – to be avoided by a wide differential diagnosis which should also include dilated cardiomyopathy.
3. The beneficial contribution of echocardiography in the differential diagnosis of heart failure in the newborns and infants was especially noted.

REFERENCES

1. **Akagi T., Benson L.N., Lightfoot N.E., et al.** – Natural history of dilated cardiomyopathy in children. *Am Heart J.* May 1991; 121(5):1502-6
2. **Cheitlin M.D., Armstrong W.F., Aurigemma G.P., Beller G.A., Bierman F.Z., Davis J.L.** – ACC/AHA/ASE 2003 guideline update for the clinical application of echocardiography: summary article: a report of the American College of Cardiology/American Heart Association Task Force on Practice Guidelines (ACC/AHA/ASE Committee to Update the 1997 Guidelines for the Clinical Application of Echocardiography). *Circulation.* Sep 2 2003; 108(9):1146-62
3. **Dimas V.V., Denfield S.W., Friedman R.A., Cannon B.C., Kim J.J., Smith E.O., et al.** – Frequency of cardiac death in children with idiopathic dilated cardiomyopathy. *Am J Cardiol.* Dec 1 2009; 104(11):1574-7
4. **Friedberg M.K., Roche S.L., Balasingam M., et al.** – Evaluation of mechanical dyssynchrony in children with idiopathic dilated cardiomyopathy and associated clinical outcomes. *Am J Cardiol.* Apr 15 2008; 101(8):1191-5
5. **Griffin M.L., Hernandez A., Martin T.C., et al.** – Dilated cardiomyopathy in infants and children. *J Am Coll Cardiol.* Jan 1988; 11(1):139-44
6. **Pahl E., Sleeper L.A., Canter C.E., et al.** – Incidence of and risk factors for sudden cardiac death in children with dilated cardiomyopathy a report from the pediatric cardiomyopathy registry. *J Am Coll Cardiol.* Feb 7 2012; 59(6):607-15