

Recurrent ventricular fibrillation as a complication of pediatric Covid-19: a case report

Saptadi Yulianto¹, Dyahris Koentartiwi¹, Herlin Kristanti¹, Dewangga Primananda Susanto¹, Takhta Khalasha², Novi Evridayanti², Emi Yulianti², Savitri Laksmi Winaputri¹, Muchammad Fahrul Udin¹, Irene Ratridewi¹, Ery Olivianto¹, Kurniawan Taufiq Kadafi¹

¹Department of Pediatrics, Medical Faculty, Universitas Brawijaya, Saiful Anwar General Hospital, Malang, Indonesia

²Department of Pediatrics, Dr. Iskak General Hospital, Tulungagung, Indonesia

Saptadi Yulianto **ORCID ID:** 0000-0003-0824-2883

ABSTRACT

Background. Coronavirus disease 2019 (Covid-19) is infrequently associated with severe complications in children. A recent observation has linked Covid-19 to recurrent ventricular fibrillation in pediatric patients.

Case report. We present a distinct case of severe Covid-19 in an 11-year-old male child who was previously healthy but obese. The patient experienced recurrent fibrillation as a complication and underwent multiple defibrillation shocks, ultimately surviving the ordeal. Early on in the management of refractory ventricular fibrillation, the patient was administered amiodarone intravenously. Upon diagnosis, he was found to have pneumonia and hypoxemic respiratory failure, necessitating supplemental oxygen through intubation due to hypoxia. Given the rapid progression of his pneumonia, a treatment regimen including remdesivir and dexamethasone was initiated.

Conclusions. This case study could be utilized as a valuable point of reference for healthcare providers treating young patients with Covid-19. It is essential to apply established treatment methods for pediatric Covid-19 to mitigate risks of complications like ventricular fibrillation in children.

Keywords: Covid-19, children, ventricular fibrillation

INTRODUCTION

The Coronavirus disease 2019 (Covid-19) has impacted individuals of various age groups globally due to the severe acute respiratory syndrome coronavirus 2 (SARS-CoV-2), with a small proportion of Covid-19 patients, initially noted at 1.7%, being children [1]. Cases of Covid-19 in children commonly exhibit mild symptoms or no symptoms at all, while critical cases may lead to respiratory failure or multiple organ dysfunction syndrome in less than 1% of patients [2]. Additionally, Covid-19 is known to induce a significant incidence of arrhythmia in affected individuals, particularly in critically ill COVID-19 patients [3].

Ventricular fibrillation (VF) is a less frequent cause of cardiac arrest in children compared to adults.

Nevertheless, VF, possibly resulting from reperfusion, can manifest during cardiopulmonary resuscitation (CPR) for asystole or pulseless electrical activity subsequent to progressive respiratory failure or shock [4]. For patients experiencing cardiac arrest with VF, the chances of successful resuscitation and survival are negatively associated with the total number of defibrillation shocks required for cardioversion [5].

We present a case of a pediatric Covid-19 patient who initially arrived at the emergency department (ED) with respiratory failure and subsequently developed recurrent ventricular fibrillation necessitating multiple defibrillation shocks and intubation.

Corresponding author:

Saptadi Yulianto

E-mail: saptadiy@ub.ac.id

Article History:

Received: 6 August 2024

Accepted: 21 August 2024

CASE PRESENTATION

An 11-year-old male child arrived at the pediatric emergency department of Dr. Iskak General Hospital with a history of dyspnea lasting 3 days and rapid breathing for 1 day. He had been experiencing a productive cough and high fever reaching up to 40.5°C for the past 3 days. However, his condition deteriorated the day prior to hospital admission as his fever and cough worsened, leading to respiratory distress. During the physical examination, he displayed signs of tachypnea (48 breaths per minute), tachycardia (120 beats per minute), hypertension (147/99 mmHg), severe subcostal retraction, nasal flaring with rales and diminished breath sounds, absence of wheezing, fever (39.2°C), and an oxygen saturation of 83% on room air. His respiratory distress escalated gradually, resulting in oxygen desaturation. Emergency intubation was performed to ensure ventilation and maintain an oxygen saturation level of $\geq 95\%$ on room air. A foley catheter was inserted and intravenous access was established. Subsequently, he was promptly transferred to the Pediatric Intensive Care Unit (PICU) for continuous monitoring and management.

The individual had no previous health issues other than being overweight (percentile; body weight, 57 kg, >97%; height, 160 cm, >97%; percentage of ideal body weight 145%). The initial findings from laboratory tests showed: white blood cell count 18,510/ μL (18.9% lymphocytes), hemoglobin 10.9 g/dL, platelet count 467,000/ μL , C-reactive protein 4.00 mg/dL (range, 0-0.5), troponin I 1.7 $\mu\text{g/L}$, and procalcitonin 0.66 ng/mL (range, 0-0.05). Cardiac biomark-

ers were within normal limits. Arterial blood gas analysis revealed pH 7.36, pCO_2 42 mmHg, pO_2 133 mmHg, and O_2 saturation 98%. A positive result was obtained from a nasopharyngeal swab RT-PCR test for SARS-CoV-2. There were no notable findings in the tests conducted for other bacterial and viral respiratory pathogens.

Upon admission to the hospital, the initial chest X-ray revealed the presence of widespread pneumonic consolidations in both lung fields and bilateral pulmonary edema. The patient's Covid-19 severity was evaluated using clinical criteria [6], which indicated a severe condition. Considering the severity, the administration of remdesivir was recommended for pediatric patients with severe Covid-19. The treatment began with a loading dose of 200 mg on the first day for patients weighing 40 kg or more, followed by 100 mg every 24 hours intravenously. The course of remdesivir therapy spanned five days, concluding on the tenth day of hospitalization. Throughout the administration of remdesivir, hepatic and renal function assessments were conducted daily, revealing no adverse effects. Despite the absence of hypotension, the patient's other vital signs remained unstable. He continued to experience persistent and recurrent fever, with limited response to antipyretics, along with tachycardia, tachypnea, and an escalating need for oxygen support. In light of these circumstances, the decision was made to introduce corticosteroids. Dexamethasone was administered at a dosage of 5 mg (0.15 mg/kg, with a maximum of 6 mg) once daily for a duration of 10 days. Additionally, broad-spectrum intravenous antibiotic therapy was initiated with ceftri-

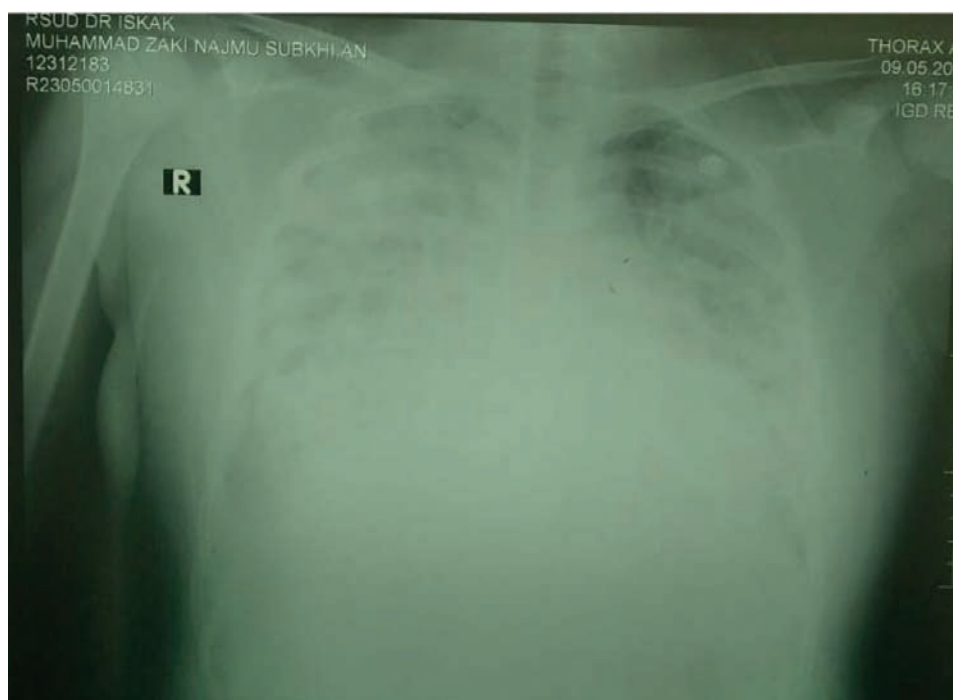


FIGURE 1. Chest X-ray of the patient shows diffuse pneumonic consolidations in both lung field and pulmonary edema bilateral

axone at a dosage of 75 mg/kg per day for a period of 5 days.

On the fourth day of hospitalization, the patient experienced an episode of ventricular fibrillation (VF) which was detected on the cardiac monitor (Figure 2).

Initial defibrillation attempts were made with a starting energy of 150 Joules (J), followed by adherence to the cardiopulmonary resuscitation (CPR) protocols outlined in the Pediatric Advanced Cardiac Life Support guidelines. Spontaneous circulation was restored 10 minutes later after four additional electric shocks and two doses of 0.5 mg adrenaline administered intravenously. The patient's blood pressure was measured at 112/84 with a pulse rate of 122 beats per minute. Despite successful resuscitation, VF reoccurred the following day, necessitating 11 shocks for successful defibrillation. The patient's blood pressure improved to 121/89 with a pulse rate of 110 beats per minute, and intravenous administration of Amiodarone at a rate of 0.5 mg/hour was initiated alongside the establishment of a central line. On the fifth hospital day, another episode of VF occurred but was successfully terminated after 7 defibrillation shocks. This time, only one shock was required for successful defibrillation. The patient's blood pressure was measured at 115/82 with a pulse rate of 109 beats per minute following

the event, and there were no further recurrences of VF thereafter.

His oxygen requirement demonstrated a gradual decrease, leading to the extubation on the seventh day of hospitalization. The administration of supplemental oxygen ceased on the tenth day of hospitalization. Absence of pneumonic consolidations was observed on the subsequent chest X-ray, and the patient's symptoms had subsided. A negative result was obtained from the follow-up PCR test for SARS-CoV-2 on the ninth day of hospitalization. Discharge from the hospital occurred on the eleventh day. During a follow-up appointment three days later, the patient was devoid of symptoms, fully oriented, and displayed normal neurological function. The patient exhibited normal blood pressure and heart rate. An electrocardiogram indicated a sinus rhythm with low-voltage QRS complexes. Echocardiographic assessment revealed mild to moderate mitral regurgitation, an ejection fraction of 40%, and ventricular enlargement and dilatation. These findings on echocardiography were suggestive of acute myocarditis (Figure 3).

DISCUSSION

A minute fraction of pediatric patients diagnosed with Covid-19 experience grave illness resulting in

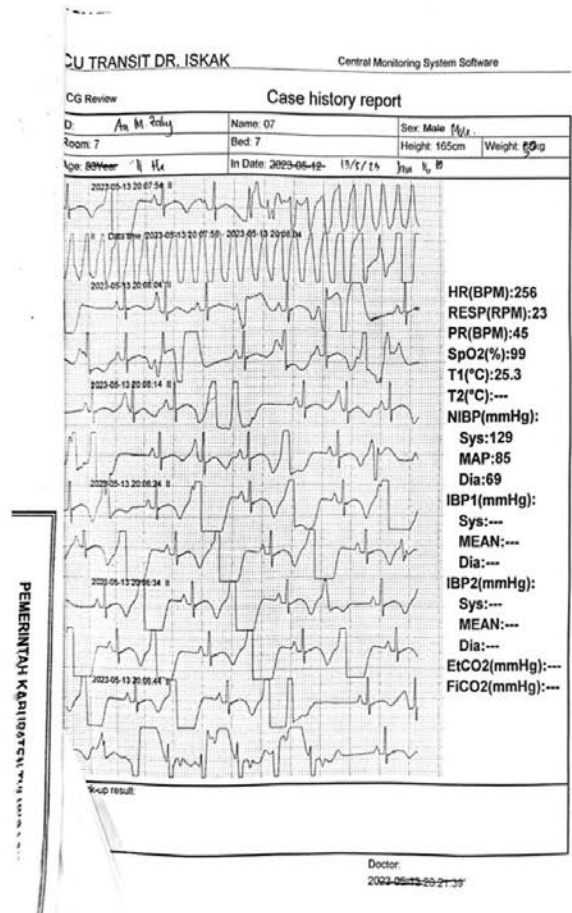
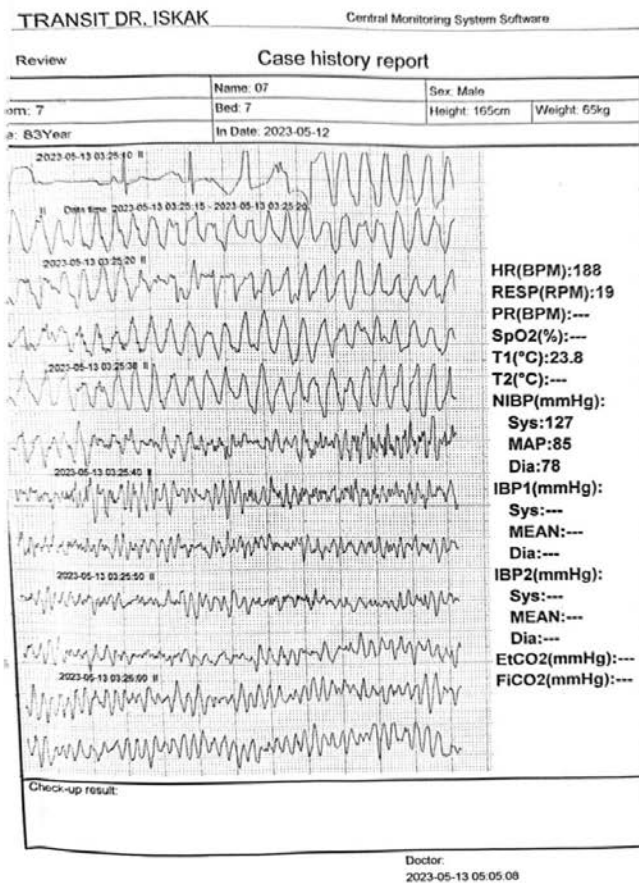


FIGURE 2. Electrocardiogram of a 11-year-old male with Covid-19 reveals ventricular fibrillation identified by arrow in lead II

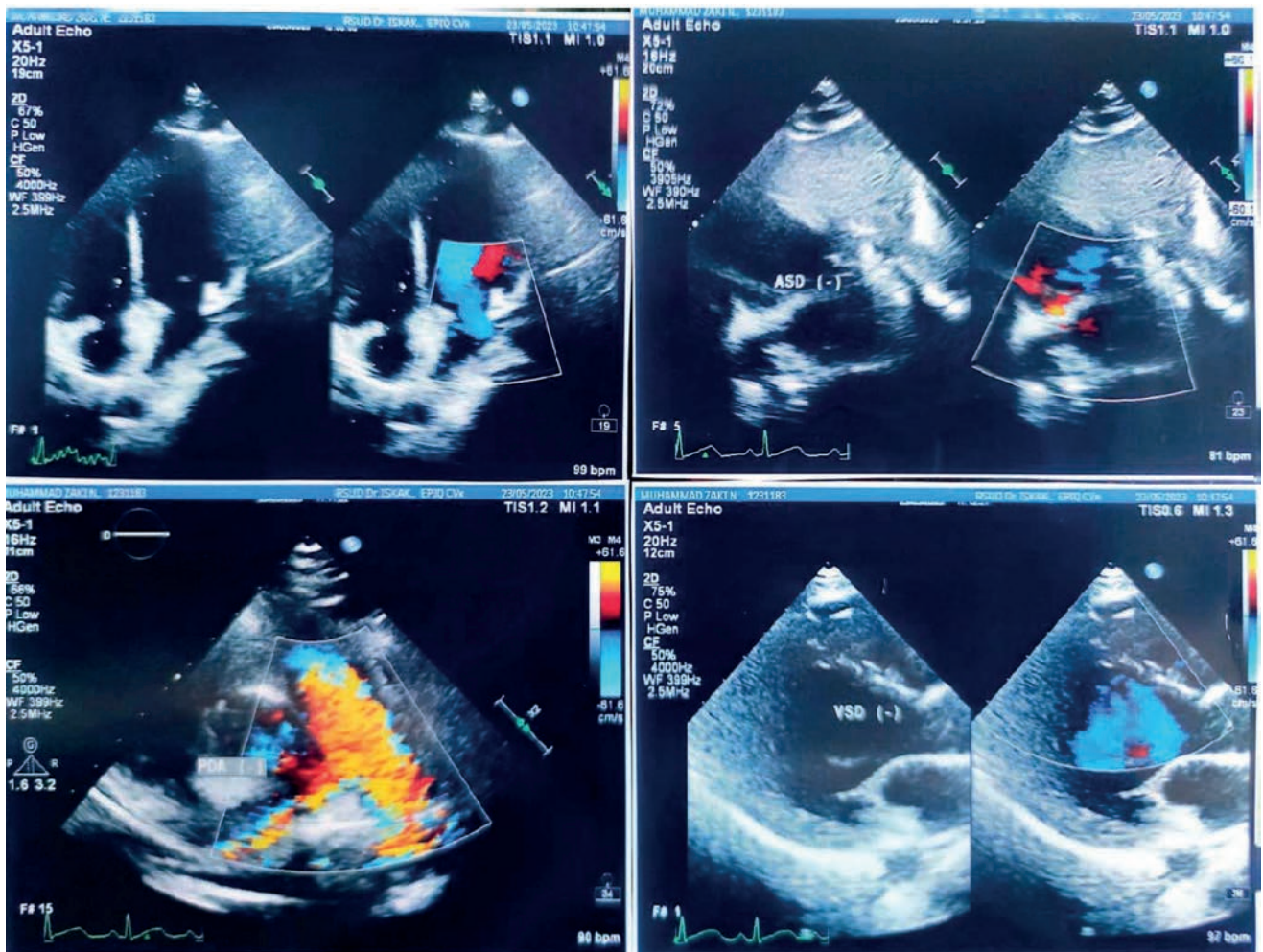


FIGURE 3. Echocardiogram of the patient suggested acute myocarditis

an unfavorable clinical prognosis, while the majority of young individuals manifest only mild symptoms. The following presentation discusses a case of critical Covid-19 in an 11-year-old male with an unremarkable medical history from Indonesia. The young patient exhibited signs of respiratory distress as his pneumonia advanced rapidly. Our primary observations indicate the presence of severe pneumonia coupled with cardiac complications such as recurrent ventricular fibrillation and acute myocarditis. Nevertheless, a thorough assessment of the patient revealed a rapid progression towards a state classified as “critical.” Subsequently, remdesivir and dexamethasone were administered with successful outcomes in the treatment of the patient.

The scope of our comprehension regarding Covid-19 lung manifestations in pediatric patients is constrained. Recent research indicates that Covid-19 pneumonia tends to be mild in children and carries a positive prognosis in individuals with good health [6,7]. A significant number of symptomatic children necessitating hospitalization exhibit a respiratory condition marked by respiratory distress, cough, and fever [8,9]. Predominant pulmonary irregularities observed on chest X-rays include ground-glass

opacities, peribronchial thickening, consolidation, and pleural effusion [10]. Children diagnosed with Covid-19 commonly experience breathlessness necessitating oxygen therapy in 30.8% of instances, with 23.1% of cases requiring intensive care unit (ICU) transfer due to organ dysfunction [11]. The most extensive study to date demonstrated that 8% of children with Covid-19 needed ICU admission and 4% required mechanical ventilation [12]. Our patient did not respond to non-invasive ventilation, leading to the diagnosis of pediatric acute respiratory distress syndrome (PARDS) and subsequent transfer to a pediatric ICU for initiation of invasive mechanical ventilation. Concerning antiviral therapy, remdesivir exhibits potent antireplicative activity against SARS-CoV-2 and is the sole FDA-approved medication for children at high risk of complications, whether hospitalized or not [13,14]. The application of remdesivir in the current case yielded a favorable response as an antiviral intervention.

Sudden arrhythmic events (ventricular fibrillation or tachycardia) are among the most common in adults and are often associated with coronary artery disease. Children rarely have coronary artery disease, and their cardiac arrests are more typically

the consequence of progressive respiratory failure or shock rather than primary arrhythmogenic event. Sudden arrhythmic events such as ventricular fibrillation or tachycardia are prevalent in the adult population and are frequently linked to coronary artery disease. Contrarily, coronary artery disease is uncommon in children, with their cardiac arrests often stemming from progressive respiratory failure or shock rather than primary arrhythmogenic incidents [4]. In instances where cardiac arrest in children goes unnoticed, idiopathic ventricular fibrillation is the most commonly identified cause, although some cases may manifest non-specific symptoms over time without a definitive diagnosis [15]. While ventricular fibrillation-related cardiac arrest is infrequent among children, constituting less than 10% of all pediatric out-of-hospital arrests, it may be linked to undetected cardiovascular issues [16]. Among children experiencing in-hospital cardiac arrest, 27% exhibit shockable rhythms of ventricular fibrillation or tachycardia [4]. The exact mechanism behind cardiac injury and the initiation of arrhythmias remains ambiguous, but there appears to be a significant systemic and myocardial inflammatory response. One research study suggested that myocardial injury mechanisms could be associated with angiotensin-converting enzyme 2 (ACE2). The mechanism behind cardiac injury remains uncertain, likely involving a combination of direct viral impact and immune-mediated damage due to inflammation [17].

Acute myocarditis, along with ventricular arrhythmias, could potentially serve as the initial clinical manifestation of Covid-19 infection [18,19]. Elevated levels of cardiac troponin in this particular patient functioned as a highly sensitive indicator of myocardial damage, in addition to the echocardiogram results indicating acute myocarditis. Myocarditis is characterized as an inflammatory condition impacting the heart, marked by inflammatory infiltrates and myocardial harm in the absence of ischemic origins [20]. The spread and propagation of the virus via the bloodstream or lymphatic system from the respiratory tract could potentially underlie the pathogenesis of myocarditis linked to SARS-CoV-2. Moreover, there is a likelihood that SARS-CoV-2 may incite an exaggerated inflammatory reaction contributing to myocardial injury. Studies have shown a notable presence of inflammatory cell infiltration within the alveoli of individuals suffer-

ing from acute respiratory distress syndrome associated with SARS-CoV-2 infection [21]. In this particular instance, corticosteroids were administered to mitigate inflammation [22]. Our patient was subjected to a 10-day regimen of dexamethasone alongside remdesivir therapy. As per prevailing recommendations, dexamethasone is advised for pediatric patients with severe Covid-19 exhibiting manifestations of hyperinflammation [23]. The judicious and timely administration of corticosteroids in conjunction with ventilatory support should be contemplated for critically ill patients to avert the onset of acute respiratory distress syndrome [21], notwithstanding the fact that corticosteroid therapy is not conventionally prescribed for SARS-CoV-2 pneumonia [24].

Our instance of severe Covid-19 pneumonia complicated by ventricular fibrillation represented an uncommon manifestation of Covid-19 infection in the pediatric population. Among children afflicted by Covid-19, a small percentage experience severe or critical illness. The cohort of pediatric Covid-19 cases progressing to respiratory deterioration, akin to our patient, remains limited. Further investigation is imperative to delineate optimal therapeutic approaches for children encountering severe or critical Covid-19 manifestations.

CONCLUSION

In summary, this clinical case report could potentially offer valuable insights for healthcare providers managing pediatric Covid-19 cases. Adherence to established therapeutic measures for pediatric Covid-19 is crucial in averting complications such as ventricular fibrillation in children.

Patient consent: Authors declare that they have obtained the written consent of the identified persons or their legal guardians for the presentation of the cases within the present scientific paper.

Conflict of interest: none declared

Financial support: none declared

Author's contributions:

Conceptualization, S.Y.; formal analysis, T.K.; investigation, D.P.S.; supervision, S.Y., D.K.; writing—original draft preparation, T.K.; writing—review and editing, S.Y.; All authors have read and agreed to the published version of the manuscript.

REFERENCES

- Bialek S, Gierke R, Hughes M, McNamara LA, Pilishvili T, Skoff T. Coronavirus Disease 2019 in Children — United States, February 12–April 2, 2020. *Morb Mortal Wkly Rep.* 2020;69:422-6. <http://doi.org/10.15585/MMWR.MM6914E4>
- Dong Y, Mo X, Hu Y, Qi X, Jiang F, et al. Epidemiology of COVID-19 Among Children in China. *Pediatrics.* 2020;145. <http://doi.org/10.1542/PEDS.2020-0702>
- Dherange P, Lang J, Qian P, Oberfeld B, Sauer WH, Koplan B, et al. Arrhythmias and COVID-19: A Review. *JACC Clin Electrophysiol.* 2020;6:1193-204. <http://doi.org/10.1016/j.jacep.2020.08.002>

4. Samson RA, Nadkarni VM, Meaney PA, Carey SM, Berg MD, Berg RA. Outcomes of In-Hospital Ventricular Fibrillation in Children. *N Engl J Med.* 2006;354:2328-39. <http://doi.org/10.1056/NEJM0A052917>.
5. Weaver WD, Cobb LA, Copass MK, Hallstrom AP. Ventricular defibrillation – a comparative trial using 175-J and 320-J shocks. *N Engl J Med.* 1982;307:1101-6. <http://doi.org/10.1056/NEJM198210283071801>
6. Sun D, Li H, Lu X-X, Xiao H, Ren J, Zhang F-R, et al. Clinical features of severe pediatric patients with coronavirus disease 2019 in Wuhan: a single center's observational study. *World J Pediatr.* 2020;16:251-9. <http://doi.org/10.1007/s12519-020-00354-4>
7. Rahimzadeh G, Ekrami Noghabi M, Kadkhodaei Elyaderani F, Navaeifar MR, Enayati AA, Manafi Anari A, et al. COVID-19 Infection in Iranian Children: A Case Series of 9 Patients. *J Pediatr Rev.* 2020;8:139-44. <http://doi.org/10.32598/JPR.8.2.139>
8. Parri N, Lenge M, Buonsenso D. Children with Covid-19 in Pediatric Emergency Departments in Italy. *N Engl J Med.* 2020;383:187-90. <http://doi.org/10.1056/NEJM2007617>
9. Tagarro A, Epalza C, Santos M, Sanz-Santaefemia FJ, Otheo E, Moraleda C, et al. Screening and Severity of Coronavirus Disease 2019 (COVID-19) in Children in Madrid, Spain. *JAMA Pediatr.* 2020;175:316-7. <http://doi.org/10.1001/JAMAPEDIATRICS.2020.1346>
10. Oterino Serrano C, Alonso E, Andrés M, Buitrago NM, Pérez Vigara A, Parrón Pajares M, et al. Pediatric chest x-ray in Covid-19 infection. *Eur J Radiol.* 2020;131:109236. <http://doi.org/10.1016/j.ejrad.2020.109236>
11. Cai X, Jiang H, Zhang S, Xia S, Du W, Ma Y, et al. Clinical manifestations and pathogen characteristics in children admitted for suspected COVID-19. *Front Med.* 2020;14:776. <http://doi.org/10.1007/S11684-020-0820-7>
12. Götzinger F, Santiago-García B, Noguera-Julían A, Lanaspá M, Lancellata L, Calò Carducci FI, et al. COVID-19 in children and adolescents in Europe: a multinational, multicentre cohort study. *Lancet Child Adolesc Health.* 2020;4(9):653-61. [http://doi.org/10.1016/S2352-4642\(20\)30177-2](http://doi.org/10.1016/S2352-4642(20)30177-2)
13. Wang Z, Zhou Q, Wang C, Shi Q, Lu S, Ma Y, et al. Clinical characteristics of children with COVID-19: a rapid review and meta-analysis. *Ann Transl Med.* 2020;8:620. <https://doi.org/10.21037/atm-20-3302>
14. FDA Approves First Treatment for COVID-19 | FDA n.d. <https://www.fda.gov/news-events/press-announcements/fda-approves-first-treatment-covid-19> (accessed March 22, 2024).
15. Hyland RJ, Chandler SF, Ladouceur VB, Jamal SM, Alexander ME, Mah DY, et al. Clinical and genetic findings in children presenting with ventricular fibrillation as the first manifestation of cardiovascular disease. *J Am Heart Assoc.* 2020;9(10):e016322. <http://doi.org/10.1161/JAHA.119.016322>
16. Meyer L, Stubbs B, Fahrenbruch C, Maeda C, Harmon K, Eisenberg M, et al. Incidence, causes, and survival trends from cardiovascular-related sudden cardiac arrest in children and young adults 0 to 35 years of age: a 30-year review. *Circulation.* 2012;126:1363-72. <http://doi.org/10.1161/CIRCULATIONAHA.111.076810>.
17. Zhu H, Rhee JW, Cheng P, Waliany S, Chang A, Witteles RM, et al. Cardiovascular Complications in Patients with COVID-19: Consequences of Viral Toxicities and Host Immune Response. *Curr Cardiol Rep.* 2020;22. <http://doi.org/10.1007/S11886-020-01292-3>
18. Hu H, Ma F, Wei X, Fang Y. Coronavirus fulminant myocarditis treated with glucocorticoid and human immunoglobulin. *Eur Heart J.* 2021;42:206. <http://doi.org/10.1093/EURHEARTJ/EHAA190>
19. Inciardi RM, Lupi L, Zaccone G, Italia L, Raffo M, Tomasoni D, et al. Cardiac Involvement in a Patient With Coronavirus Disease 2019 (COVID-19). *JAMA Cardiol.* 2020;5:819-24. <http://doi.org/10.1001/JAMACARDIO.2020.1096>
20. Esfandiarei M, McManus BM. Molecular biology and pathogenesis of viral myocarditis. *Annu Rev Pathol.* 2008;3:127-55. <http://doi.org/10.1146/ANNUREV.PATHMECHDIS.3.121806.151534>.
21. Xu Z, Shi L, Wang Y, Zhang J, Huang L, Zhang C, et al. Pathological findings of COVID-19 associated with acute respiratory distress syndrome. *Lancet Respir Med.* 2020;8:420-2. [http://doi.org/10.1016/S2213-2600\(20\)30076-X](http://doi.org/10.1016/S2213-2600(20)30076-X).
22. Souza TH, Nadal JA, Nogueira RJN, Pereira RM, Brandão MB. Clinical manifestations of children with COVID-19: A systematic review. *Pediatr Pulmonol.* 2020;55:1892-9. <http://doi.org/10.1002/ppul.24885>.
23. Dulek DE, Fuhlbrigge RC, Tribble AC, Connelly JA, Loi MM, El Chebib H, et al. Multidisciplinary Guidance Regarding the Use of Immunomodulatory Therapies for Acute COVID-19 in Pediatric Patients. *J Pediatric Infect Dis Soc.* 2020;9:716-37. <http://doi.org/10.1093/JPIDS/PIAA098>
24. Wu F, Zhao S, Yu B, Chen YM, Wang W, Song ZG, et al. A new coronavirus associated with human respiratory disease in China. *Nature.* 2020;579(7798):265-9. <http://doi.org/10.1038/s41586-020-2008-3>