

PECULIARITIES OF DIAGNOSIS AND TREATMENT OF THE ESOPHAGEAL FOREIGN BODIES (COINS) IN CHILDREN – CLINICOSTATISTICAL STUDY

Corneliu Toader^{1,3}, Miorita Toader², Iolanda Cristina Vivisenco^{2,3}

¹National Institute of Neurology and Neurovascular Diseases, Bucharest

²“Grigore Alexandrescu” Emergency Hospital for Children, Bucharest

³“Carol Davila” University of Medicine and Pharmacy, Bucharest

ABSTRACT

Objective. The authors performed a clinical and statistical study on cases of esophageal foreign bodies, with particular reference to ingested coins, admitted and treated in the ENT Department of the “Grigore Alexandrescu” Emergency Hospital for Children, between 01.01.2006 – 01.08.2007.

Method and materials. A retrospective study, involving the interpretation and corroboration of the clinical and paraclinical findings of each case study.

Results. Of all cases of foreign bodies, coins held the highest percentage; the average length of stay in hospital was 2 days; there were no cases of major complications (esophageal perforation, bleeding by intercepting a large vessel, mediastinitis); were also recorded particular cases that required special attention.

Conclusion. All cases were approached and resolved by rigid endoscopy; shortening the time elapsed before presenting to ENT specialist facilitates the therapeutic approach, dramatically lowering the risk of complications; X-ray examination, although essential, can sometimes provide incomplete information, the diagnosis certainty being ensured only by endoscopy.

Keywords: esophageal foreign bodies, coins, therapeutic approach, child

INTRODUCTION

Esophageal foreign bodies (EFB) are one of the major emergencies in pediatric ENT specialty, both by consequences generated by the occlusion of the esophageal lumen (denutrition, dehydration), but also by redoubtable complications that can occur: esophageal perforation, mediastinitis, bleeding by intercepting a large vessel. The risk of these complications increases with each day of delay in diagnosis and treatment (1).

Often, ingested foreign bodies pass spontaneously through the esophagus, due to its mobility and distensibility. Common causes of foreign body impaction in the esophagus are determined by:

- Large size (for coins)
- Particular shapes (especially those having sharp edges)

- Changes in the esophageal lumen (most common post-caustic esophageal stenosis) (1,2).
- In children, the coins have the highest percentage of all ingested foreign bodies (up to 75%, according to statistics) (3). This might be explained by:
- Large diameter of the coin compared to the esophageal lumen, in children,
- Special attraction exerted by the coins on children – especially on those younger than 4 years old (small, bright, noisy, accessible, easily maneuvered objects).

METHOD AND MATERIALS

We performed a clinical and statistical study on cases of esophageal foreign bodies in children, with

particular reference to ingested coins, admitted and treated in the ENT Department of the “Grigore Alexandrescu” Emergency Hospital for Children, Bucharest.

The choice of this study was suggested to us by the large number of esophageal foreign bodies that were sent to our department during the period.

Our study included 102 cases of esophageal foreign bodies hospitalized during 01.01.2006 – 01.08.2007, 46 of them being cases of ingested coins.

RESULTS

Gender distribution showed a predominance in boys (60.8%) than in girls (39.2%) (results comparable with literature data). As regards the boy: girl ratio in the particular case of ingested coins, this was kept almost unchanged (62% boys, 38% girls) (Fig. 1).

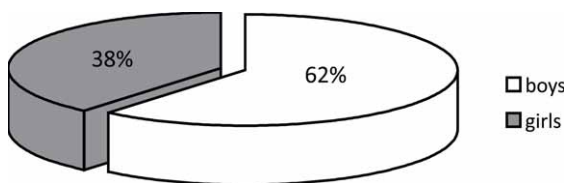


FIGURE 1. Distribution of study group by gender

In that period, the number of cases of EFB coming from urban environment was almost double than the number of cases coming from rural environment (Fig. 2).

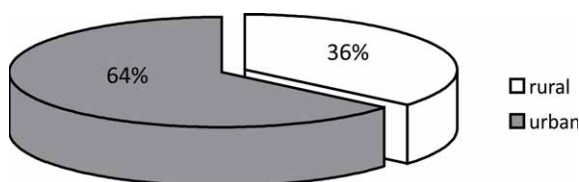


FIGURE 2. Distribution of study group by rural/urban environment

We used the following classification for foreign bodies:

- Coins
- Other metallic objects (hair clips, paper clips, keys, staples, etc.)
- Plastic (usually toy fragments)
- Vegetal (seeds, straws, fruit or vegetable peels)
- Food bolus
- Bones.

We considered appropriate the following distribution of age groups: 0-1 year, 1-4 years, 4-7 years, more than 7 years old.

The results are shown in Table 1 and Figure 3.

TABLE 1. Esophageal foreign body classification

Age groups \ EFB	coins	other metallic objects	plastic	ve-ge-tal	food bolus	bones	Total
0-1 year	0	2	2	0	0	1	5
1-4 years	37	5	7	8	2	2	61
4-7 years	6	1	5	3	4	1	20
> 7 years	3	1	1	2	9	0	16
Total	46	9	15	13	15	4	102

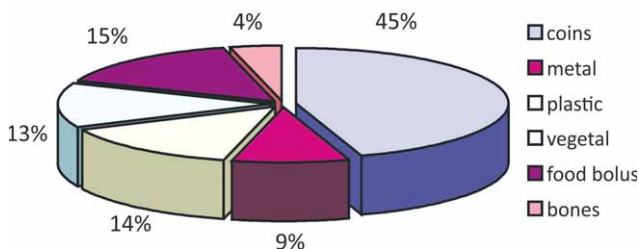


FIGURE 3. Esophageal foreign body classification by their nature

In the age group 0-1 year we found the lowest number of EFB and no case of coin ingestion.

Age group 1-4 years has held the top spot in statistics in terms of the total number of cases of EFB (61 of 102). In this age group, coins held the highest percentage of all cases of EFB (Fig. 4). Of the total cases of coins throughout the study group, this age group (1-4 years) holds “absolute record” (80%) (Fig. 5).

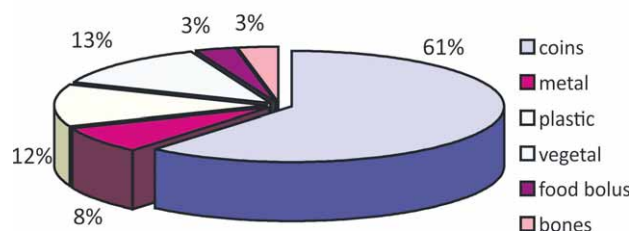


FIGURE 4. Percentage distribution of EFB in children 1-4 years old

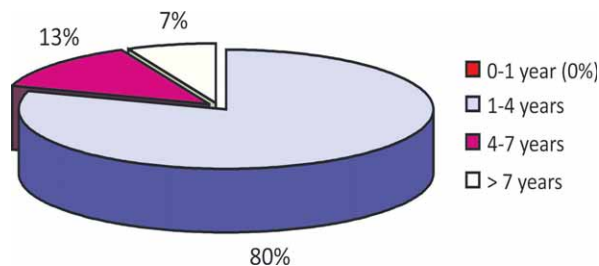


FIGURE 5. Percentage distribution of EFB by age groups

In age group 4-7 years, we find that both total EFB cases (20 cases) and the percentage of ingested coins of the total number of cases of EFB in this age group (13%) are decreasing. Note that 4 of

20 cases of EFB were diagnosed in patients with known post-caustic esophageal stenosis.

After age 7 years, we found a significant similarity with the situation encountered in adults (as percentage, food bolus holds the first place, especially in children with known post-caustic esophageal stenosis) and the number of coins is decreasing dramatically (3 cases). Note that 5 of the 16 cases of EFB were found in patients with known post-caustic esophageal stenosis (Fig. 6).

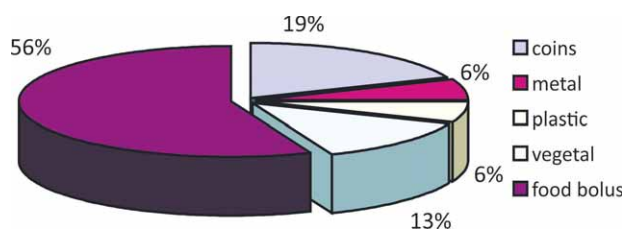


FIGURE 6. Percentage distribution of EFB in children > 7 years old

X-ray examination performed on admission revealed the presence of coins in the esophagus and their location, being essential for guiding the endoscopist (Fig. 7). We note two particular cases where both front and lateral X-ray views indicated the presence of a single coin, the “surprise” being revealed by endoscopy, which highlighted 3 coins of 1 ban in one case, and 1 coin of 50 bani and 3 coins of 10 bani in the other case.

Presentation in the ENT Department for coin ingestion was done relatively quickly (average time being about 2 days after ingestion). We noted one exception: a child 1 year and 4 months old from rural environment who came to the hospital 14 days after ingestion, with deterioration of the general condition and severe denutrition and dehydration.

There was no case of major complications (esophageal perforation, mediastinitis, bleeding by intercepting a large vessel) – nor on admission in our clinic or during extraction maneuvers for the foreign body (rigid endoscopy). Further evolution was favorable, with rapid restoration of esophageal transit.

However, we noticed some situations that have required special attention:

- The 14 days old coin generated a substantial granulation tissue, which was friable and bleeding, making the endoscopist activity harder. Extraction was performed with difficulty and massive postoperative antibiotic protection was set till full recovery.
- The 2 cases in which lateral X-ray view could not correctly identify the actual number of

coins, this one being an intrainterventional surprise.

All cases of EFB were approached by rigid endoscopy. Although various non-endoscopic methods for EFB removal are described in the literature (bougienage pushing the foreign body into the stomach, Foley catheter use, etc.), each of these methods presents a risk and if they fail, subsequent endoscopic approach for EFB extraction becomes more difficult (4,5).

In 4 of 46 cases of coin ingestion, the endoscopy has not detected the presence of a foreign body, because the relaxation induced by general anesthesia allowed spontaneous passage of the esophagus, with subsequent radiological confirmation.

The average length of stay in hospital for coin ingestion was 2 days.

DISCUSSION

In this personal study, the age group 1-4 years recorded the highest percentage of EFB (61 of 102 cases) and also the highest percentage of ingested coins (37 of 46 cases) compared to other age groups. The explanation is offered by the well-known tendency of this age group to explore the environment, including by putting things in their mouth, as well as by their psychomotor instability that triggers frequent bouts of crying or laughing, which facilitate swallowing or aspiration of a foreign body. In addition, children in this age group are drawn to coins due to their characteristics: brightness, noise, accessibility, easy maneuverability.

Delay in presentation to the physician makes extraction maneuvers more difficult due to exuberant granulation tissue, which becomes friable and bleeding and due to changes (by oxidation) in coin appearance – it loses its luster and changes color, being more difficult to be detected.

X-ray examination – although essential, can sometimes provide incomplete information, the diagnosis certainty being ensured only by endoscopy.

Rigid endoscopy remains the method of choice for solving this pathology in children.

The net predominance of cases coming from urban environment drew our attention. We intend to pursue this issue in the future, to see if we can consider a new “social phenomenon”: extremely demanding pace of professional life for young parents and the large number of hours allocated for work drop, implicitly, the amount of time and attention given for child supervision, this one being therefore more exposed to risk.

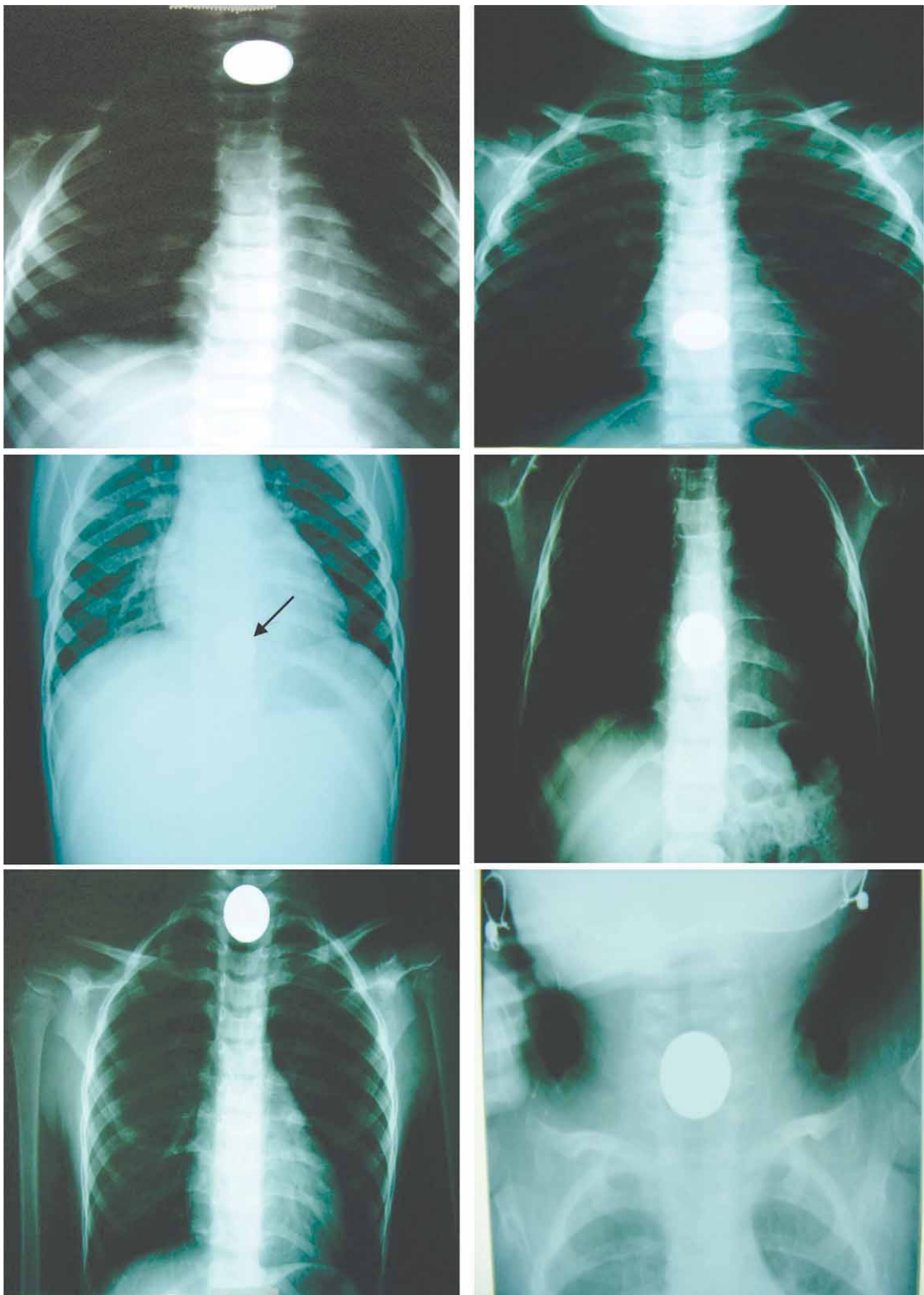


FIGURE 7. Coins in the esophagus – X-ray examination

CONCLUSION

We believe that an action plan is needed in order to educate people about the severity of EFB in children. An issue often minimized by parents and con-

sidered easy to be solved by the doctor may be, in fact, a major event with significant risk for the patient, requiring great skill and experience from the specialist.

REFERENCES

1. **Buruiană M., Ivanovici M., Mustatea N.** Otorinolaringologie pediatrică All, editor.; 1998.
2. **Paparella's textbook of otolaryngology: Sauder; 1990.**
3. **Cummings C.** Textbook of Otorhinolaryngology - *Head and Neck Surgery*: Mosby; 2005.
4. **Dahshan A.H., Kevin Donovan G.** Bougienage versus endoscopy for esophageal coin removal in children. *J Clin Gastroenterol.* 2007; 41(5): p. 454-6.
5. **Harned R.K., Strain J.D., Hay T.C.** Esophageal foreign bodies: safety and efficacy of Foley catheter extraction of coins. *AJR Am J Roentgenol.* 1997; 168(2): p. 443-6.